

EFFECT OF HESPERETIN TREATMENT ON BLOOD GLUCOSE LEVEL, SPERMATOOZOA QUALITY, AND SPERMATOOZOA QUANTITY

by Nerdy N Linta M, Bunga Rimta B, Puji Lestari S Ginting , Peny A, Vriezka
M, Tedy Kurniawan B

Submission date: 06-Apr-2021 05:43AM (UTC+0700)

Submission ID: 1551339244

File name: 18406-63943-1-PB.pdf (321.36K)

Word count: 5187

Character count: 28920

EFFECT OF HESPERETIN TREATMENT ON BLOOD GLUCOSE LEVEL, SPERMATOZOA QUALITY, AND SPERMATOZOA QUANTITY IN ALLOXAN-INDUCED DIABETIC MICE

Nerdy Nerdy^{1*}, Linta Meliala¹, Bunga Rimta Barus¹, Puji Lestari¹, Selamat Ginting², Peny Ariani³, Vriezka Mierza⁴, and Tedy Kurniawan Bakri⁵

¹Department of Pharmacy, Faculty of Pharmacy, Institut Kesehatan Deli Husada, Deli Serdang, Indonesia

²Department of Public Health, Faculty of Public Health, Institut Kesehatan Deli Husada, Deli Serdang, Indonesia

³Department of Midwifery, Faculty of Midwifery, Institut Kesehatan Deli Husada, Deli Serdang, Indonesia

⁴Department of Pharmacy, Faculty of Pharmacy, Universitas Tjut Nyak Dhien, Sei Sikambing, Medan, Indonesia

⁵Department of Pharmacy, Faculty of Mathematics and Natural Sciences, Universitas Syiah Kuala, Banda Aceh, Indonesia

*Corresponding author: nerdy190690@gmail.com

ABSTRACT

Male infertility has occurred rapidly in the last few decades, primarily in developing countries. An antioxidant, hesperetin is a flavonoid that is found in abundance in orange peels. The aims of this research were to determine the effect of hesperetin on blood sugar levels, spermatozoa quality, and spermatozoa quantity. The research structure included induction of diabetes mellitus and treatment for 8 weeks, followed by determination of blood sugar levels, spermatozoa quality, and spermatozoa quantity. Hesperetin has the ability to restore blood sugar levels, spermatozoa quantity, seminiferous tubules diameter, and testicular weight, volume, and germinal epithelial layer thickness with significant difference from the normal control group. Hesperetin did not fully restore spermatozoa motility, viability, and morphology with significant difference from the normal control group, nor from the positive control group. However, overall, hesperetin decreased blood glucose levels, increased spermatozoa quantity, and improved the spermatozoa quality in alloxan-induced diabetes mellitus mice. Dose-dependent activity was observed with the optimum dose at 200 mg/kg body weight.

Key words: alloxan, blood glucose, diabetic, hesperetin, spermatozoa

ABSTRAK

Peningkatan kejadian infertilitas secara pesat terhadap kaum pria yang mayoritas terjadi pada negara berkembang dalam beberapa dekade terakhir. Hesperetin merupakan flavonoid yang terdapat dalam jumlah melimpah dari bahan alam kulit jeruk. Penelitian ini bertujuan mengetahui pengaruh pemberian hesperetin terhadap kadar gula darah, kualitas spermatozoa, dan kuantitas spermatozoa. Alur penelitian mencakup induksi diabetes mellitus dan perlakuan selama 8 minggu, yang selanjutnya dilakukan pemeriksaan kadar gula darah, kualitas spermatozoa dan kuantitas spermatozoa. Hesperetin dapat memulihkan kadar gula darah, kuantitas spermatozoa, massa testikular, volume testikular, diameter tubulus seminiferous, dan ketebalan lapisan epitel germinal testikular yang tidak berbeda signifikan dengan kelompok kontrol normal. Kelompok pemberian hesperetin tidak dapat memulihkan motilitas spermatozoa, viabilitas spermatozoa, dan morfologi spermatozoa yang berbeda signifikan dengan kelompok kontrol normal, namun tidak berbeda signifikan dengan kelompok kontrol positif. Hesperetin menurunkan kadar gula darah, meningkatkan kuantitas spermatozoa, dan memperbaiki kualitas spermatozoa, pada tikus diabetes mellitus yang diinduksi dengan aloksan dengan aktivitas yang bergantung terhadap dosis dan dosis optimum 200 mg/kg berat badan.

Kata kunci: aloksan, gula darah, diabetes, hesperetin, spermatozoa

INTRODUCTION

Diabetes mellitus is a chronic disease and one of the most important public health problems to be resolved globally. Diabetes mellitus has a very high prevalence in Indonesia (Ligita *et al.*, 2019). Diabetes mellitus increases morbidity and mortality along with complications in various organs. Malfunction of male reproductive organs is one of the most widely reported complications in people with diabetes mellitus and can cause infertility in men and women (Deyhoul *et al.*, 2017). Previous research on diabetes mellitus finds that decreases in the hormone testosterone and disruption of spermatogenesis are closely related to uncontrolled increases in blood glucose levels (Salimnejad *et al.*, 2017; Soliman *et al.*, 2019).

Hyperglycemia can also interfere with hypothalamus-pituitary-gonad axis function and cause local damage to the proliferation of Leydig and Sertoli cells. Leydig and Sertoli cells are intratesticular functional cells that have a role in testosterone biosynthesis and spermatogenesis (Petersen *et al.*,

2015). Flavonoid is a compound which is found to reduce blood glucose level by antioxidant activity, recovering spermatozoa abnormalities caused by diabetes mellitus (Sarian *et al.*, 2017; Jalili *et al.*, 2018). Hesperetin is a class of flavonoid that can reduce blood sugar levels and can be extracted abundantly from citrus fruit peels (Meneguzzo *et al.*, 2020). However, the effect of hesperetin on spermatozoa, and spermatozoa disorders caused by alloxan-induced diabetes mellitus in testes, is not yet known. Based on the findings above, the researchers are interested to examine the effect of hesperetin treatment on blood glucose level, spermatozoa quality, and spermatozoa quantity in alloxan-induced diabetes mellitus mice (*Mus musculus* L.).

MATERIALS AND METHODS

This study used 48 male mice obtained from the Department of Pharmacy at Universitas Sumatera Utara, Medan, Indonesia. Average age and weight for the mice were 60 days \pm 5 days and 30 \pm 5 g,

respectively. Mice were placed in a plastic cage covered with husks; husks were changed twice a week. The cage was covered with wire and the mice were given food and drink *ad libitum* every day in accordance with the Ethical Clearance from the Department of Biology at Universitas Sumatera Utara.

The experiment used a completely randomized design with 8 treatments composed of 3 controls (normal, negative, and positive) and 5 treatments of hesperetin (Sigma Aldrich) in various concentrations. The number of treatments and replications in both tests fulfilled the Federer formula, $(t-1) \times (n-1) \geq 15$. Each treatment was replicated 6 times. The distribution of each treatment is C(0): normal control (without alloxan (Sigma Aldrich) induction and without treatment); C(-): negative control (with alloxan induction and without treatment); C(+): positive control (with alloxan induction and 150 mg/kg metformin treatment); T(1): treatment one (with alloxan induction and 50 mg/kg hesperetin treatment); T(2): treatment two (with alloxan induction and 100 mg/kg hesperetin treatment); T(3): treatment three (with alloxan induction and 150 mg/kg hesperetin treatment); T(4): treatment four (with alloxan induction and 200 mg/kg hesperetin treatment); and T(5): treatment five (with alloxan induction and 250 mg/kg hesperetin treatment).

Alloxan solution in water was administered to the animals by intramuscular induction with a dose of 150 mg/kg body weight. Blood glucose level was checked on the 7th day after induction using a glucometer. The tail of each mouse was cleaned with cotton dipped in warm water. Blood from the tail tip dripped onto a strip test and was read with a glucometer. Mice with blood glucose levels >200 mg/dL were diabetic and ready to be tested. The test-ready mice were given an extract according to the treatment dose. Hesperetin was dissolved with water and given to the mice orally at 0.3 mL for 8 weeks. During 8 weeks trial, the blood glucose level of mice was measured once a week after the mice fasted for 24 hours.

The Examination of Sperm Quality

Mice were killed by anaesthetic with ether and neck dislocation before being operated on to isolate the testes and epididymis. The epididymis was taken from the testes, and spermatozoa samples were taken immediately after operating by slicing and pressing the cauda epididymis slowly. Spermatozoa motility, viability, morphology, and quantity were then observed. Testicular weight and volume, diameter of seminiferous tubules, and thickness of testicular germinal epithelial layer were also determined. These methods were modified from Nak-Ung *et al.* (2018); and Al-Saeed *et al.* (2019).

Observation of spermatozoa motility was performed using a 23 fold magnification microscope. Spermatozoa motility was calculated by the formula $(A + B) = (A + B + C + D) \times 100$. The motility of spermatozoa was grouped into the categories: fast progressive (A), slow progressive (B), non-progressive (C), and immotile spermatozoa (D) as they were counted. Observations of spermatozoa viability was conducted by placing one

drop of spermatozoa sample in a petri dish. One drop of 0.9% NaCl solution was added and mixed using a glass rod. The suspension was observed.

Morphology of spermatozoa was examined as follows: spermatozoa suspensions were placed on a glass object, to which 1 drop of 70% methanol was added. This was fixed to dry with Canadian balsam and covered with a glass cover. The number of normal spermatozoa and abnormal spermatozoa was observed under a microscope with a 100-fold magnification microscope. The results obtained were calculated with the formula $a = (a + b) \times 100$. Spermatozoa morphology was grouped into the categories normal morphology (a) and abnormal morphology (b). Normal mouse spermatozoa consist of a head (caput) that forms a hook like head, a short middle section, and a very long cauda.

For measuring the spermatozoa quantity, suspended spermatozoa were homogenized with 0.9% NaCl. Then 0.1 mL of the sample was added to the Neubauer improved hemocytometer and topped with a glass cover. Under a light microscope with a 100-fold magnification, a hemocytometer was placed and the number of spermatozoa was counted in rooms 1, 2, 3, 4, and 5. The spermatozoa quantity was calculated by $N = 2 \times 10^5$. N is the number of spermatozoa calculated in boxes 1, 2, 3, 4, and 5 on the Neubauer improved hemocytometer.

The Examination of Testicle

The testicular weight was measured by weighing the testes. The testicular volume was calculated by measuring the length and width of the testes, using a calliper and millimetre paper. The testicular volume was calculated according to the formula $(\pi \times W^2 \times L) = 6$. The testicular volume in mm³ was determined with π , testicular width (W), and testicular length (L).

Preparations of testicular histology were carried out using the paraffin method with hematoxylin eosin double stain. The paraffin method required fixation, washing, dehydration, purification, paraffin infiltration, implantation, incision, sticking, deparaffinization, staining, closing, and labelling.

The diameter of the seminiferous tubules and the thickness of the testicular germinal epithelial layer were determined using a 100x microscope and computer program Axiocam 8.0. Measurements were conducted on seminiferous tubules which were round or close to each other. Figure 1 shows the overview of the seminiferous tubules diameter and testicular germinal epithelial layer thickness. D is the diameter of the seminiferous tubules; E is the thickness of the testicular germinal epithelial layer with Hematoxylin Eosin and 100x magnification (Altöe *et al.*, 2014).

Data Analysis

Data were arranged with the software Statistical Product and Service Solutions. The observed data were analyzed statistically using the parametric analysis of variance test. If the results were significant, analysis continued via Duncan test with degree of significance $\alpha = 0.05$.

RESULTS AND DISCUSSION

The blood glucose level in the negative control group, positive control group, and the treatment group after alloxan induction was greater compared to the normal group without alloxan induction. This might be observed because alloxan compound is toxic and can damage pancreatic β cells which produce insulin (Lenzen, 2008). Figure 2 shows the blood glucose level with various treatments from the first week to the eighth week.

After alloxan induction, blood glucose levels increased in the negative control group, positive control group, and treatment groups. Hesperetin and metformin treatments in alloxan-induced mice resulted in lower blood glucose levels than in the negative alloxan-induced control group. In the final week, it was found the hesperetin and metformin treatment groups had significantly reduced blood glucose levels ($P < 0.05$). The antidiabetic effect of hesperetin at 200 mg/kg body weight was not significantly different from the antidiabetic effect of metformin with dose 150 mg/kg body weight. In the eighth week, antidiabetic effects of hesperetin at all doses were not significantly different from the normal control group. Flavonoid acted as an active antidiabetic compound triggered insulin production and reduced blood glucose levels (Al-Ishaq et al., 2019; Caro-Ordieres et al., 2020).

All hesperetin treatment groups and metformin treatment groups declined in blood glucose level from

the first week (35). The greatest decrease in glucose level occurred in the 250 mg/kg hesperetin treatment group. The higher the dose, the greater the antidiabetic effect, indicating that flavonoid antidiabetic activity is dose dependent (Ahmed et al., 2012). As antioxidants, flavonoids play a role in lowering blood glucose levels (Banjarnahor and Artanti, 2014). Flavonoids can also prevent damage to insulin-producing β -cells by suppressing β cell apoptosis without changing the proliferation of pancreatic β cells (Gregory and Kelly, 2011). Oral antidiabetic drugs can trigger diabetic complications, including reproductive system disorders (Maiorino et al., 2014; Bahar et al., 2020). Therefore, antidiabetic drugs also have the potential to treat reproductive system disorders for people with diabetes (Meneses et al., 2015).

The spermatozoa quality and quantity decreased after alloxan induction. High blood glucose level disrupts blood flow due to vessel damage in several parts of the body, affecting spermatogenesis (Mangoli et al., 2013). Table 1 shows spermatozoa motility, viability, normal morphology, and quantity in the eight week, with various treatments. Table 2 shows the testicular weight, volume, and germinal epithelium thickness, along with the diameter of seminiferous tubule in the eighth week, with various treatments.

Compared to the negative control group, the hesperetin treatment groups significantly affected the percentage of spermatozoa motility, viability, normal morphology, and quantity, as well as testicular weight,

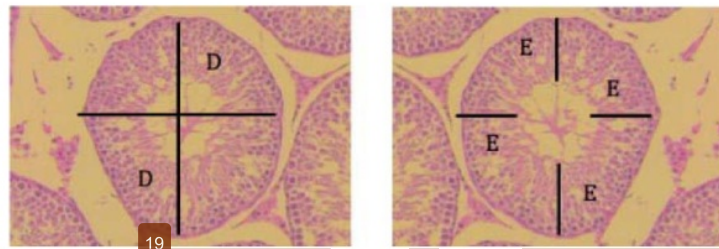


Figure 1. Overview of seminiferous tubules diameter and testicular germinal epithelium thickness

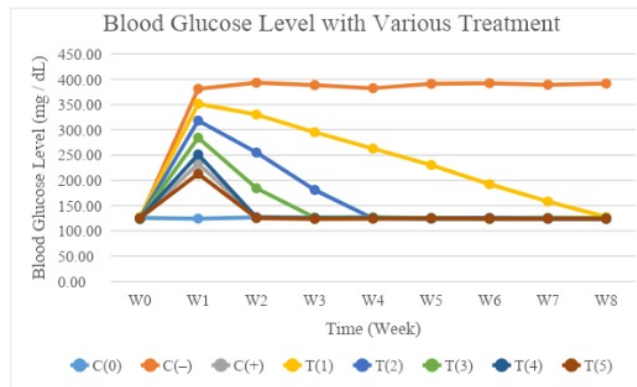


Figure 2. Blood glucose levels with various treatments from the first week to the eighth week. C(0)= Normal control (without alloxan and treatment); C(-)= Negative control (with alloxan and without treatment); C(+)= Positive control (with alloxan and with metformin 150 mg/kg body weight); T(1)= Treatment one (with alloxan and with hesperetin 50 mg/kg body weight); T(2)= Treatment two (with alloxan and hesperetin 100 mg/kg body weight); T(3)= Treatment three (with alloxan and hesperetin 150 mg/kg body weight); T(4)= Treatment four (with alloxan and with hesperetin 200 mg/kg body weight); and T(5)= Treatment five (with alloxan and hesperetin 250 mg/kg body weight)

Table 1. The spermatozoa motility, viability, normal morphology, and quantity in the eighth week, with various treatments

Treatment	Motility (%)	Viability (%)	Normal morphology (%)	Quantity (n)
C(0)	81.32±13.03 ^a	98.31±3.56 ^a	97.55±1.82 ^a	253.15±51.35 ^a
C(-)	50.25±8.05 ^b	65.14±2.36 ^b	70.11±1.31 ^b	133.22±27.02 ^b
C(+)	64.05±10.26 ^c	89.33±3.24 ^c	88.93±1.66 ^c	249.12±50.53 ^a
T(1)	53.05±8.50 ^b	77.52±2.81 ^d	75.31±1.41 ^d	167.31±33.94 ^c
T(2)	57.77±9.26 ^d	82.24±2.98 ^c	79.96±1.49 ^c	201.19±40.81 ^d
T(3)	60.31±9.66 ^d	86.29±3.13 ^c	84.34±1.57 ^f	225.18±45.68 ^c
T(4)	63.82±10.23 ^c	88.82±3.22 ^c	89.02±1.66 ^c	266.21±54.00 ^a
T(5)	68.02±10.90 ^c	90.01±3.26 ^c	92.35±1.72 ^c	312.14±63.32 ^f

^{a, b, c, d, e, f} Different superscripts within the same column indicate significant differences ($P < 0.05$). C(0)= Normal control (without alloxan and treatment); C(-)= Negative control (with alloxan and without treatment); C(+)= Positive control (with alloxan and with metformin 150 mg/kg body weight); T(1)= Treatment one (with alloxan and with hesperetin 50 mg/kg body weight); T(2)= Treatment two (with alloxan and hesperetin 100 mg/kg body weight); T(3)= Treatment three (with alloxan and hesperetin 150 mg/kg body weight); T(4)= Treatment four (with alloxan and with hesperetin 200 mg/kg body weight); and T(5)= Treatment five (with alloxan and hesperetin 250 mg/kg body weight)

Table 2. The testicular weight, volume, and germinal epithelial layer thickness, in addition to the diameter of seminiferous tubules in the eighth week, with various treatments

Treatment	Testicular weight (mg)	Testicular volume (mm ³)	Diameter (μm)	Thickness (μm)
C(0)	135.15±5.37 ^a	145.05±27.15 ^a	556.17±91.24 ^a	150.34±28.22 ^a
C(-)	99.23±3.94 ^b	82.31±15.41 ^b	331.29±54.35 ^b	64.51±12.11 ^b
C(+)	134.84±5.36 ^a	146.34±27.39 ^a	475.16±77.95 ^c	123.51±23.18 ^c
T(1)	107.14±4.26 ^c	105.34±19.72 ^c	400.16±65.65 ^d	96.55±18.12 ^d
T(2)	118.35±4.70 ^d	124.16±23.24 ^d	443.14±72.70 ^c	109.24±20.51 ^c
T(3)	134.14±5.33 ^a	144.92±27.13 ^a	479.02±78.58 ^c	122.94±23.08 ^c
T(4)	135.24±5.37 ^a	146.55±27.43 ^a	516.12±84.67 ^f	135.28±25.39 ^f
T(5)	135.08±5.37 ^a	145.34±27.20 ^a	560.15±91.89 ^a	148.22±27.82 ^a

volume, germinal epithelial layer thickness, and diameter of seminiferous tubules after alloxan induction and hesperetin treatment ($P < 0.05$). Hesperetin treatment fully recovered the spermatozoa quantity, along with seminiferous tubules diameter and testicular weight, volume, and germinal epithelial layer thickness compared to the normal control. Hesperetin treatment could not fully recover but closely resembled the spermatozoa motility, viability, and normal morphology of the normal control. However, the effect of 200 mg/kg hesperetin treatment was not significantly different from 150 mg/kg metformin treatment. Hesperetin treatment improved spermatozoa quantity and quality compared to the negative control. This corroborates previous studies which reveal that plant extracts with high flavonoid content can significantly improve spermatozoa quality and quantity (Benko *et al.*, 2019).

Flavonoids can affect the process of spermatozoa transport to increase motility (Jofré *et al.*, 2019). Adenosine triphosphatase enzyme maintains internal homeostasis for sodium and potassium ions. Ion concentrations maintain the ability of the membrane to transport dissolved materials across the cell membrane. A disrupted sperm membrane interferes with the transport of spermatozoa essential nutrients (Saez *et al.*, 2011; Delpire and Gagnon, 2018). Alloxan induction causes damage to the cells of the pancreas, interferes with insulin production, causes hyperglycemia, and increases reactive oxygen species. Reactive oxygen species damage the mitochondrial membrane, potentially causing a loss of function which can induce sperm cell apoptosis (Loeken, 2012; Noh *et al.*, 2020).

Flavonoids thought to increase testosterone production play an important role in spermatozoa

viability. They maintain the epididymis, which is a temporary storage area for mature spermatozoa, allowing them to survive until they are excreted through the penis (Martin and Touaibia, 2020). Good epididymis function increases the percentage of spermatozoa viability. When dye is applied, viable sperm will appear colourless, however, non-viable sperm will appear red due to the entry of dye across the damaged sperm head membrane (Popal and Nagy, 2013).

Increased spermatozoa abnormalities may also occur due to various disturbances, particularly during spermatogenesis at spermiogenesis (Abdelhamid *et al.*, 2019). The shape of the spermatozoa changes based on decreased testosterone levels, on which the epididymis also depends. Thus decreased testosterone levels cause abnormal spermatozoa morphology (Orieke *et al.*, 2019). Flavonoid can repair spermatozoa morphology by decreasing free radical activity. This increases fertility and decreases the percentage of abnormal spermatozoa. It produces a positive feedback loop that also leads to increased testosterone levels (Olayinka *et al.*, 2019). The normal shape of the spermatozoa will directly affect the spermatozoa motility and integrity (Jakubik-Uljasz *et al.*, 2020). Spermatozoa morphology also plays a role in fertilization, wherein if the abnormal number of spermatozoa is too high, fertility will decrease (Alahmar, 2019).

Flavonoid increases spermatozoa quantity because of hypoglycemic activity; flavonoid reduces the blood glucose level in diabetic mice (Shi *et al.*, 2019). Phytochemicals such as flavonoids increase the number of spermatozoa in mice due to antioxidant activity in which they neutralize free radicals (Biagi *et al.*, 2019). Antioxidants are hydrogen and electron donors for free

radicals and thus they neutralize free radical activity (Aryal *et al.*, 2019).

Increased testicular weight is probably due to the increased activity of spermatogenic cells that make up the structure and the weight of the testicles. Spermatogenic cells also increase spermatogonia and increase testicular weight (Parhizkar *et al.*, 2014). Flavonoid increases testicular weight by increasing secretion of gonadotropin releasing hormone that can affect the anterior pituitary, which in turn creates follicle stimulating hormone and luteinizing hormone (Das and Kumar, 2018). Luteinizing hormone maintains the growth of Leydig cells, increases follicle stimulating hormone, maintains spermatogenesis, and increases testicular weight (Ramaswamy and Weinbauer, 2014).

Citrus flavonoid has antioxidant properties that restore testicular volume after exposure to certain substances (Gandhi *et al.*, 2020). Testicular volume is related to semen quality, which is influenced by male sexual libido. The existence of repeated stimulation increases the gonadotropin hormone, which induces the hormone testosterone for optimum spermatogenesis (Dutta *et al.*, 2019; Swee and Quinton, 2019). Semen fluid is secreted from the accessory gland stimulated by testosterone. Semen production and the volume are related to testicular volume (Noda, 2019).

Diameter and thickness of seminiferous tubules are determined by the interaction between follicle stimulating hormone and luteinizing hormone (Oduwole *et al.*, 2018; Kalwar *et al.*, 2019). If follicle stimulating hormone is not produced, luteinizing hormone fails to maintain homeostasis, causing the diameter of the seminiferous tubules to shrink. Normal levels of follicle stimulating hormone maintain the diameter and the thickness of the seminiferous tubules (Gupta and Verma, 2018). A diabetic condition can inhibit supply of nutrients to the testicles and disrupt spermatogenesis (Ding *et al.*, 2015). Flavonoids provide antioxidant effects which restore the diameter and thickness of seminiferous tubules because antioxidant compounds neutralize free radicals (Gayatri *et al.*, 2017).

CONCLUSION

Hesperetin decreases blood glucose levels, increases spermatozoa quantity, and improves spermatozoa quality in alloxan-induced diabetes mellitus mice. Activity was dose-dependent with the optimum dose observed at 200 mg/kg body weight. It is recommended that the next study be conducted with a longer treatment period to see the extent of damage to the reproductive organs due to complications of alloxan-induced diabetes.

ACKNOWLEDGEMENT

The authors thank Institut Kesehatan Deli Husada Deli Tua for the research grant and Mutiara Mukti Farma Industri Farmasi for research tools and material support.

REFERENCES

- Abdelhamid, M.H.M., M. Walschaerts, G. Ahmad, R. Mieusset, L. Bujan, and S. Hamdi. 2019. Mild experimental increase in testis and epididymis temperature in men - effects on sperm morphology according to spermatogenesis stages. *Transl. Androl. Urol.* 8(6):651-665.
- Ahmed, O.M., A.M. Mahmoud, A. Abdel-Moneim, and M.B. Ashour. 2012. Antidiabetic effects of hesperidin and naringin in type 2 diabetic rats. *Diabetol. Croat.* 41(2):53-67.
- Al-Ishaq, R.K., M. Abotaleb, P. Kubatka, K. Kajo, and D. Büsselberg. 2019. Flavonoids and their antidiabetic effects - cellular mechanisms and effects to improve blood sugar levels. *Biomolecules.* 9(9):1-35.
- Al-Saeed, M.H., M.A. Kadhem, and A.H. Al-Saeed. 2019. Study the effect of ethanolic extract of *Ceratonia siliqua*, glimepiride and metformin on semen fluid quality in diabetic male guinea pig induced by alloxan. *Bas. J. Vet. Res.* 18(2):208-233.
- Alahmar, A.T. 2019. Role of oxidative stress in male infertility - an updated review. *J. Hum. Reprod. Sci.* 12(1):4-18.
- Altoe, P.M., E.D. Tatsuo, D.N.S. Paulo, R. Jarske, M. Milagres, and I.D. Loureiro. 2014. Effects of human chorionic gonadotropin on the normal testicular tissue of rats. *Acta Cir. Bras.* 29(5):292-298.
- Aryal, S., M.K. Baniya, K. Danekhu, P. Kunwar, R. Gurung, and N. Koirala. 2019. Total phenolic content, flavonoid content and antioxidant potential of wild vegetables from Western Nepal. *Plants.* 8(4):1-12.
- Bahar, A., F. Elyasi, M. Moosazadeh, G. Afradi, and Z. Kashi. 2020. Sexual dysfunction in men with type 2 diabetes. *Caspian J. Int. Med.* 11(3):295-303.
- Banjarnahor, S.D.S. and N. Artanti. 2014. Antioxidant properties of flavonoids. *Med. J. Indones.* 23(4):239-244.
- Benko, F., V. Palkovičová, M. Ďuračka, J. Árvay, N. Lukáč, and E. Tvrdá. 2019. Antioxidant effects of marigold (*Calendula officinalis*) flower extract on the oxidative balance of bovine spermatozoa. *Contemp. Agric.* 68(3-4):92-102.
- Biagi, M., D. Noto, M. Corsini, G. Bainsi, D. Cerretani, G. Cappellucci, and E. Moretti. 2019. Antioxidant effect of the *Castanea sativa* Mill. leaf extract on oxidative stress induced upon human spermatozoa. *Oxid. Med. Cell. Longev.* Doi: 10.1155/2019/8926075.
- Caro-Ordieres, T., G. Marín-Royo, L. Opazo-Ríos, L. Jiménez-Castilla, J.A. Moreno, C. Gómez-Guerrero, and J. Egido. 2020. The coming age of flavonoids in the treatment of diabetic complications. *J. Clin. Med.* 9(9):1-30.
- Das, N. and T.R. Kumar. 2018. Molecular regulation of follicle stimulating hormone synthesis, secretion and action. *J. Mol. Endocrinol.* 60(3):131-155.
- Delpire, E. and K.B. Gagnon. 2018. Water homeostasis and cell volume maintenance and regulation. *Curr. Top. Membr.* 81:3-52.
- Deyhoul, N., T.M. Doost, and M. Hosseini. 2017. Infertility related risk factors: A systematic review. *Int. J. Women's Health Reprod. Sci.* 5(1):24-29.
- Ding, G.L., Y. Liu, M.E. Liu, J.X. Pan, M.X. Guo, J.Z. Sheng, and H.F. Huang. 2015. The effects of diabetes on male fertility and epigenetic regulation during spermatogenesis. *Asian J. Androl.* 17(6):948-953.
- Dutta, S., P. Sengupta, and S. Muhamad. 2019. Male reproductive hormones and semen quality. *Asian Pac. J. Repro.* 8(5):189-194.
- Gandhi, G.R., A.B.S. Vasconcelos, D.T. Wu, H.B. Li, P.J. Antony, H. Li, F. Geng, R. Q. Gurgel, N. Narain, and R.Y. Gan. 2020. Citrus flavonoids as promising phytochemicals targeting diabetes and related complications-a systematic review of in vitro and in vivo studies. *Nutrients.* 12(11):2907.
- Gayatri, P.R., S.A. Sudjarwo, and R. Itishom. 2017. Potency of ethanol extract of dayak onion (*Eleutherine americana* Merr) as protector of testosterone level, diameter and thickness of seminiferous tubule in mice induced with lead acetate. *J. Appl. Sci. Res.* 5(4):43-51.
- Gupta, P.C. and A. Verma. 2018. Potential parameters in assessment of testicular toxicity. *Biomed. J. Sci. Tech. Res.* 7(3):5915-5918.
- Gregory, S. and N.D. Kelly. 2011. Quercetin. *Altern. Med. Rev.* 16(2):172-194.

- Jakubik-Uljasz, J., K. Gil, A. Rosiak-Gill, and M. Piasecka. 2020. Relationship between sperm morphology and sperm DNA dispersion. **Transl. Androl. Urol.** 9(2):405-415.
- Jofré I., M. Cuevas, L.S. de Castro, J.D. de Agostini Losano, M.A. Torres, M. Alvear, E. Scheuermann, A.F.C. Andrade, M. Nichi, M.E.O. Assumpção, and F. Romero. 2019. Antioxidant effect of a polyphenol rich murtilla (*Ugni molinae* Turcz.) extract and its effect on the regulation of metabolism in refrigerated boar sperm. **Oxid. Med. Cell. Longev.** Doi: 10.1155/2019/2917513.
- Kalwar, Q., M. Chu., A.A. Ahmad, X. Ding, X. Wu, P. Bao, and P. Yan. 2019. Morphometric evaluation of spermatogenic cells and seminiferous tubules and exploration of luteinizing hormone beta polypeptide in testis of datong yak. **Animals.** 10(1):66.
- Lenzen, S. 2008. The Mechanisms of alloxan and streptozotocin induced diabetes. **Diabetologia.** 51(2):216-226.
- Ligita, T., K. Wicking, K. Francis, N. Harvey, and I. Nurjannah. 2019. How people living with diabetes in Indonesia learn about their disease - a grounded theory study. **Plos One.** 14(2):1-19.
- Loeken, M.R. 2012. A new role for pancreatic insulin in the male reproductive axis. **Diabetes.** 61(7):1667-1668.
- Maiorino, M.I., G. Bellastella, K. Esposito. 2014. Diabetes and sexual dysfunction: Current perspectives. **Diabetes Metab. Syndr. Obes. Targets Ther.** 7:95-105.
- Mangoli, E., A.R. Talebi, M. Anvari, and M. Pourtezar. 2013. Effects of experimentally-induced diabetes on sperm parameters and chromatin quality in mice. **Iran J. Reprod. Med.** 11(1):53-60.
- Martin, L.J. and M. Touaibia. 2020. Improvement of testicular steroidogenesis using flavonoids and isoflavonoids for prevention of late onset male hypogonadism. **Antioxidants (Basel).** 9(3):1-17.
- Meneguzzo, F., R. Ciriminna, F. Zabini, and M. Pagliaro. 2020. Review of evidence available on hesperidin rich products as potential tools against covid-19 and hydrodynamic cavitation based extraction as a method of increasing their production. **Processes.** 8(5):549.
- Meneses, M.J., M. Sousa, M.G. Alves, and P.F. Oliveira. 2015. The antidiabetic drug metformin and male reproductive function: An overview. **Int. J. Diabetol. Vasc. Dis. Res.** 3(1):1-2.
- Jalili, C., M. Kamani, S. Roshankhah, H. Sadeghi, and M.R. Salahshoor. 2018. Effect of *Falcaria vulgaris* extracts on sperm parameters in diabetic rats. **Andrologia.** 50(10):13130.
- Nak-Ung, S., N. Nakprom, C. Maneengam, S. Nudmamud-Thanoi, and S. Thanoi. 2018. Changes in sperm quality and testicular structure in a rat model of type 1 diabetes. **Asian Biomed.** 12(4):141-147.
- Noda, T. and M. Ikawa. 2019. Physiological Function of seminal vesicle secretions on male fecundity. **Reprod. Med. Biol.** 18(3):241-246.
- Noh, S., A. Go, D.B. Kim, M. Park, H.W. Jeon, and B. Kim. 2020. Role of antioxidant natural products in management of infertility: A review of their medicinal potential. **Antioxidants.** 9(10):1-61.
- Oduwale, O.O., H. Peltoketo, and I.T. Huhtaniemi. 2018. Role of follicle stimulating hormone in spermatogenesis. **Front. Endocrinol. (Lausanne).** 9:1-11.
- Olayinka, E.T., A. Ore, O.A. Adeyemo, and O.S. Ola. 2019. The role of flavonoid antioxidant, morin in improving procabazine induced oxidative stress on testicular function in rat. **Porto Biomed. J.** 4(1):1-8.
- Orieke, D., O.C. Ohaeri, I.I. Ijeh, and S.N. Ijioma. 2019. Semen quality, hormone profile and histological changes in male albino rats treated with *Corchorus olitorius* leaf extract. **Avicenna J. Phytomed.** 9(6):551-562.
- Parhizkar, S., S.B. Zulkifli, and M.A. Dollah. 2019. Testicular morphology of male rats exposed to *Phaleria macrocarpa* aqueous extract. **Iran J. Basic Med. Sci.** 17(5):384-390.
- Petersen P.M., K. Seierøe, and B. Pakkenberg. 2015. The total number of leydig and sertoli cells in the testes of men across various age groups - a stereological study. **J. Anat.** 226(2):175-179.
- Popal, W. and Z.P. Nagy. 2013. Laboratory processing and intracytoplasmic sperm injection using epididymal and testicular spermatozoa: What can be done to improve outcomes. **Clinics (Sao Paulo).** 68(1):125-130.
- Ramaswamy, S. and G.F. Weinbauer. 2014. Endocrine control of spermatogenesis: Role of follicle stimulating hormone and luteinizing hormone or testosterone. **Spermatogenesis.** 4(2):1-15.
- Saez, F., A. Ouvrier, and J.R. Drevet. 2011. Epididymis cholesterol homeostasis and sperm fertilizing ability. **Asian J. Androl.** 13(1):11-17.
- Salimnejad, R., G. Sazegar, M.J.S. Borujeni, S.M. Mousavi, F. Salehi, and F. Ghorbani. 2017. Protective effect of hydroalcoholic extract of *Teucrium polium* on diabetes induced testicular damage and serum testosterone concentration. **Int. J. Reprod. Biomed.** 15(4):195-202.
- Sarian, M.N., Q.U. Ahmed, S.Z.M. So'ad, A.M. Alhassan, S. Murugesu, V. Perumal, S.N.A.S. Mohamad, A. Khatib, and J. Latip. 2017. Antioxidant and antidiabetic effects of flavonoids - a structure activity relationship based study. **Biomed. Res. Int.** 2017:8386065.
- Shi, G.J., Y. Li, Q.H. Cao, H.X. Wu, X.Y. Tang, X.H. Gao, J.Q. Yu, Z. Chen, and Y. Yang. 2020. In vitro and in vivo evidence that quercetin protects against diabetes and its complications - a systematic review of the literature. **Biomed. Pharmacother.** 109:1085-1099.
- Soliman, G.A., A.S. Saeedan, R.F. Abdel-Rahman, H.A. Ogaly, R.M. Abd-Elsalam, and M.S. Abdel-Kader. 2019. Olive leaves extract attenuates type 2 diabetes mellitus induced testicular damage in rats - molecular and biochemical study. **Saudi Pharm. J.** 27(3):326-340.
- Swee, D.S. and R. Quinton. 2019. Managing congenital hypogonadotropic hypogonadism: A contemporary approach directed at optimizing fertility and long-term outcomes in males. **Ther. Adv. Endocrinol. Metab.** 10:1-15.

EFFECT OF HESPERETIN TREATMENT ON BLOOD GLUCOSE LEVEL, SPERMATOOZOA QUALITY, AND SPERMATOOZOA QUANTITY

ORIGINALITY REPORT

12%

SIMILARITY INDEX

6%

INTERNET SOURCES

10%

PUBLICATIONS

1%

STUDENT PAPERS

PRIMARY SOURCES

- 1

P.P. Preetha, V. Girija Devi, T. Rajamohan.
"Comparative effects of mature coconut water
(Cocos nucifera) and glibenclamide on some
biochemical parameters in alloxan induced
diabetic rats", Revista Brasileira de
Farmacognosia, 2013
Publication

1%
- 2

www.scielo.br
Internet Source

1%
- 3

Yeni Susanti, Merryana Adriani, Annis Catur
Adi. "Effect of Single Clove Garlic Extract
(Allium Sativum Linn) on Blood Sugar Levels,
Malondialdehyde, Insulin Levels and Insulin
Resistance (Experiments in Rats (Rattus
Novergicus) Induced by Streptozotocin",
STRADA Jurnal Ilmiah Kesehatan, 2020
Publication

<1%
- 4

worldwidescience.org
Internet Source

<1%

5	aecl.org.au Internet Source	<1 %
6	"Male Infertility", Springer Science and Business Media LLC, 2020 Publication	<1 %
7	"Taurine 10", Springer Science and Business Media LLC, 2017 Publication	<1 %
8	Sureeporn Nak-ung, Nutnicha Nakprom, Chonikan Maneengam, Sutisa Nudmamud-Thanoi, Samur Thanoi. "Changes in sperm quality and testicular structure in a rat model of type 1 diabetes", Asian Biomedicine, 2019 Publication	<1 %
9	Submitted to Syiah Kuala University Student Paper	<1 %
10	www.pubmedcentral.nih.gov Internet Source	<1 %
11	Reed, D.A.. "Inhibition of testicular growth and development in Manduca sexta larvae parasitized by the braconid wasp Cotesia congregata", Journal of Insect Physiology, 19970219 Publication	<1 %
12	Submitted to Sriwijaya University Student Paper	<1 %

13	sipora.polije.ac.id Internet Source	<1 %
14	worldresearchersassociations.com Internet Source	<1 %
15	www.omicsonline.org Internet Source	<1 %
16	dagensdiabetes.se Internet Source	<1 %
17	E. D. L. Putra, N. Nazliniwaty, F. R. Harun, N. Nerdy. "QUANTIFICATION OF ISOORIENTIN IN THREE VARIETIES OF PASSION FRUIT PEEL ETHANOLIC EXTRACT BY HIGH PERFORMANCE LIQUID CHROMATOGRAPHY MASS SPECTROMETRY", Rasayan Journal of Chemistry, 2020 Publication	<1 %
18	doaj.org Internet Source	<1 %
19	Mohammad Mazani, Masoud Ojarudi, Shokofeh Banaei, Ramin Salimnejad, Milad Latifi, Hanieh Azizi, Lotfollah Rezagholizadeh. "The protective effect of cinnamon and ginger hydro-alcoholic extract on carbon tetrachloride-induced testicular damage in rats", Andrologia, 2020 Publication	<1 %

20

Sefa Kucukler, Cuneyt Caglayan, Ekrem Darendelioğlu, Fatih Mehmet Kandemir. "Morin attenuates acrylamide-induced testicular toxicity in rats by regulating the NF-κB, Bax/Bcl-2 and PI3K/Akt/mTOR signaling pathways", Life Sciences, 2020

Publication

<1 %

21

www.tandfonline.com

Internet Source

<1 %

22

Chongde Sun, Chao Zhao, Esra Capanoglu Guven, Paolo Paoli et al. "Dietary polyphenols as antidiabetic agents: Advances and opportunities", Food Frontiers, 2020

Publication

<1 %

23

Florensia Niwele, Putri Sintaria Sitepu, Adelina Simamora, Kris Herawan Timotius, Adit Widodo Santoso. "Nutritional Enzymes Inhibitory Activities of Fruit Juice and Fruit Pulp Extract of Muntingia Calabura L.", Current Research in Nutrition and Food Science Journal, 2020

Publication

<1 %

24

Soudeh Ghafouri-Fard, Hamed Shoorei, Mahdi Mohaqiq, Moloud Tahmasebi, Mohammad Seify, Mohammad Taheri. "Counteracting effects of heavy metals and antioxidants on male fertility", BioMetals, 2021

Publication

<1 %

25	Zhigang Hu, Jing Liu, Junting Cao, Huilin Zhang, Xiaolin Liu. "Ovarian transcriptomic analysis of black Muscovy duck at the early, peak and late egg-laying stages", Gene, 2021 Publication	<1 %
26	ecerm.org Internet Source	<1 %
27	eprints.umm.ac.id Internet Source	<1 %
28	journals.sagepub.com Internet Source	<1 %
29	mafiadoc.com Internet Source	<1 %
30	pericles.pericles-prod.literatumonline.com Internet Source	<1 %
31	www.researchsquare.com Internet Source	<1 %
32	Cyrus Jalili, Mehran Kamani, Shiva Roshankhah, Hamid Sadeghi, Mohammad Reza Salahshoor. " Effect of extracts on sperm parameters in diabetic rats ", Andrologia, 2018 Publication	<1 %
33	Maria Schubert, Sophie Kaldewey, Lina Pérez Lanuza, Henrike Krenz et al. " Does the c.-211G > T polymorphism impact Sertoli cell	<1 %

number and the spermatogenic potential in infertile patients? ", Andrology, 2020

Publication

34

Toru Maruyama. "Bracing adolescent idiopathic scoliosis: A systematic review of the literature of effective conservative treatment looking for end results 5 years after weaning", Disability and Rehabilitation, 2009

Publication

<1 %

35

Yewen Zhou, Di Zhang, Dehao Sun, Sheng Cui. "Zearalenone affects reproductive functions of male offspring via transgenerational cytotoxicity on spermatogonia in mouse", Comparative Biochemistry and Physiology Part C: Toxicology & Pharmacology, 2020

Publication

<1 %

36

"Minutes of The 43rd General Assembly of The European Association for The Study of Diabetes", Diabetologia, 2008

Publication

<1 %

37

Fatemeh Gholizadeh, Sanaz Dastghaib, Farhad Koohpeyma, Elahe Bayat, Pooneh Mokarram. "The protective effect of Stevia rebaudiana Bertoni on serum hormone levels, key steroidogenesis enzymes, and testicular damage in testes of diabetic rats", Acta Histochemica, 2019

Publication

<1 %

Exclude quotes On

Exclude matches Off

Exclude bibliography On